

# The Importance of Flowmetry in Carotid Body Tumor Surgery: A Case Report

## *Karotid Body Tümörü Cerrahisinde Flowmetrenin Önemi: Olgu Sunumu*

Abdurrahim Colak<sup>1</sup>, Munacettin Ceviz<sup>1</sup>, Necip Becit<sup>1</sup>, Aysenur Dostbil<sup>2</sup>, Hikmet Kocak<sup>1</sup>

<sup>1</sup>Department of Cardiovascular Surgery, Faculty of Medicine, Ataturk University, Erzurum, Turkey

<sup>2</sup>Department of Anesthesiology, Faculty of Medicine, Ataturk University, Erzurum, Turkey

### Abstract

Carotid body tumors arise from the embryonic neural crest. These tumors are mostly benign, and they rarely show character. Bifurcation of the carotid body cells originates from a common carotid paraganglion; a tumoral mass lateral to the carotid bifurcation is usually found in the neck. A pathologic feature of these tumors is that they have a tendency to wrap because they are not treated with the external and internal carotid arteries. In our clinic, we operated on a patient who had been diagnosed with carotid body tumor. After removal of the internal carotid artery, the mass flow due to a decrease in the light of literature used to evaluate the importance of flowmetry carotid surgery.

**Key Words:** Carotid artery, Carotid body tumor, Flowmetry

### Özet

Karotid body tümörleri embriyolojik nöral krestten kaynaklanan ve çoğunlukla benign karakter gösteren nadir tümörlerdir. Karotid bifurkasyondaki karotid cismin paraganglionik hücrelerinden kaynaklanırlar; tümoral kitle olarak genellikle boyun lateralinde ve karotid bifurkasyonda bulunurlar. Patolojik lokalizasyonun özelliği nedeni ile tedavi edilmediklerinde bu tümörler eksternal ve internalkarotid arterleri sarma eğilimi gösterirler. Kliniğimizde karotid body tm tanısıyla opere ettiğimiz hastamızda, operasyon esnasında kitlenin çıkarıldıktan sonra internalkarotis arterdeki akımın azalmasına bağlı kullandığımız flowmetrenin karotistomi cerrahisindeki önemini literatürler ışığında değerlendirmeyi amaçladık.

**Anahtar Kelimeler:** Karotis arter, Karotis vücut tümörü, Flowmetre

### Introduction

Carotid body tumors are rare tumors that are often located in the bifurcation of the common carotid artery and develop from paraganglionic cells of the carotid body. These tumors originate from the mesodermal elements of the neural ectoderm; they are located at the base of or posteromedial to the carotid bifurcation. Because of the well-developed vascular structures in this area, blood flow and oxygen consumption in carotid body tumors are greater than in brain tumors [1]. These tumors have a poor metastatic potential. They have been reported to exhibit malignant changes 3% to 10% of the time, and this change leads to metastasis in 2% of cases [2, 3].

When discussing surgical treatment, the patient's age, dimensions of the mass, symptoms, and potential complications must all be considered. The internal carotid artery should be protected or repaired with the saphenous vein or a synthetic graft.

### Case Report

A 45-year-old female patient was admitted to our clinic after diagnosis of a carotid body tumor. This diagnosis was established with the use of Doppler ultrasonography by the referring clinic; ultrasonography was performed due to swelling and a palpable mass on the left side of her neck. Examination revealed a palpable mass of approximately 4x4 cm on the left side of the patient's neck. Doppler ultrasonography showed a hypoechoic, homogenous, and smooth contoured solid mass lesion of 37x24x39 mm in size in the left carotid bifurcation. The left external carotid artery was displaced medially and the left internal carotid artery was displaced laterally as a result of the lesion. With magnetic resonance angiography, the tumor was reported to be a carotid body tumor of approximately 43x30x40 mm in size in the left carotid bifurcation that included the internal carotid artery and displaced it laterally (Figure 1). The tumor was classified as Shamblin Type II. The patient's hematologic values were normal, and she was operated on under general anesthesia.

**Received:** March 18, 2012 / **Accepted:** June 06, 2012

**Correspondence to:** Abdurrahim Colak, Department of Cardiovascular Surgery, Faculty of Medicine, Ataturk University, Erzurum, Turkey

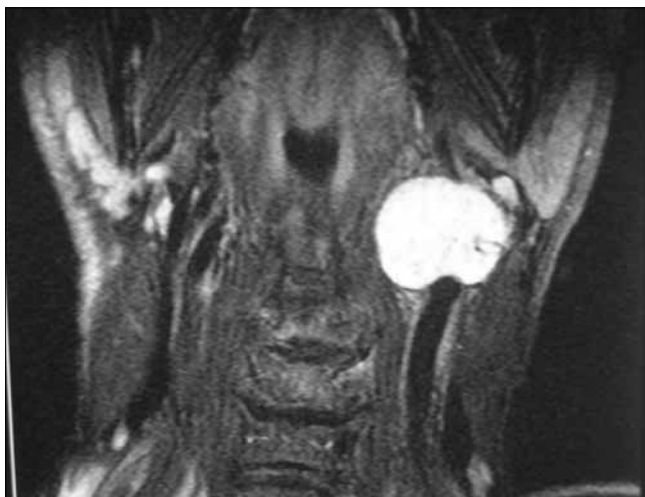
Phone: +90 442 316 63 33-2145 Fax: +90 442 316 63 40 e-mail: colaka@atauni.edu.tr

doi:10.5152/eajm.2012.28

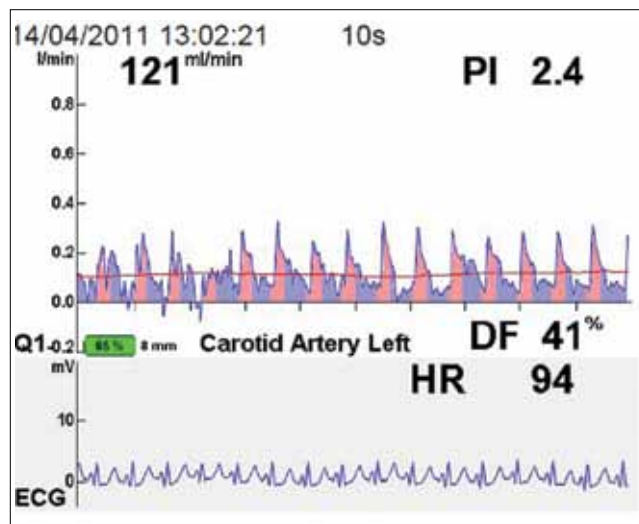
The lower left of the mass was stained standing for the saphenous graft, and it was taken in a sterile cover. The tumor was accessed from an incision of approximately 5 cm made along the medial aspect of the sternocleidomastoid muscle. The tumor was excised using ultrasonic cautery. The flows were then measured with a flowmeter because of poor internal carotid pulse and kinking of the artery after tumor removal. The flow in the external carotid artery was found to be good, whereas the internal carotid flow was poor (Figure 2). The diastolic flow was also found to be low. At this point, the saphenous graft was removed and prepared. The patient received 1 mg/kg of heparin, and the carotid artery was clamped. A segment approximately 2 cm from the bifurcation was opened transversely, and patch plasty was performed with the saphenous graft. After the clamps were removed, the flows were again measured. The internal carotid artery and diastolic flow were both improved and increased (Figure 3). When bleeding was controlled, the layers were closed normally, and the patient was taken to the intensive care unit and intubated. The patient was extubated 3 hours postoperatively, taken to the recovery unit on the first day postoperatively, and discharged on the fourth day postoperatively.

## Discussion

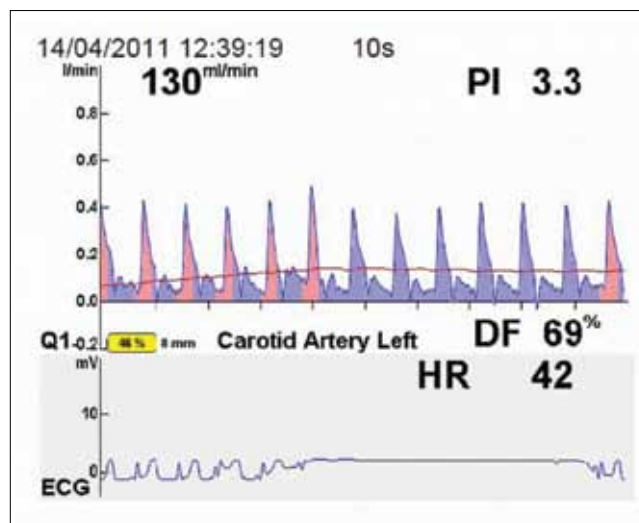
Carotid body tumors are slow-growing tumors. They are located anterior to the sternocleidomastoid muscle at the level of the hyoid bone, and they cause regional pain. Symptoms of dysphagia, odynophagia, and dysphonia, as well as the compression of the 9<sup>th</sup> and 12<sup>th</sup> cranial nerves, may be seen as the tumor grows [4, 5]. Ultrasonography, technetium isotope scintigraphy, computed tomography, magnetic resonance imaging, angiography, and conventional angiog-



**Figure 1.** Magnetic resonance angiography of the carotid body tumor.



**Figure 2.** The flow in the internal carotid artery.



**Figure 3.** The internal carotid artery and diastolic flow.

raphy (as needed) are among the diagnostic methods that are used with these tumors. The incidence of carotid body paragangliomas is less than 0.5% of all tumors. The head and the neck are the second most common locations of paragangliomas. The incidence is approximately 5% in both of the carotid arteries, but this rate increases to 33% in instances of an autosomal-dominant type that has demonstrated familial transmission [6]. Regionally located diseases such as brachial cysts, parotid gland tumors, carotid artery aneurysms, lateral aberrant thyroid glands, malignant lymphoma, neurofibroma, tuberculous lymphadenitis, and metastatic carcinoma should be considered in the differential diagnosis of carotid tumors during the preoperative period [7]. We did not perform a

biopsy for diagnostic purposes in our patient because biopsy contraindicated for carotid body tumors. Carotid body tumors have been classified by Shamblin and colleagues according to their growth patterns [8]. Type I tumors are regional and easily removed; this type accounts for 26% of the tumors. Type II tumors surround the carotid arteries and are adhesive. These are difficult to excise and account for 40% of cases. Type III tumors make up 27% of cases; these are adhesive, completely surround the carotid arteries, and can be removed only with a difficult surgery that requires graft placement into the internal carotid artery. Our patient was assessed as having a Shamblin Type II tumor.

The current method for the surgical treatment of a carotid body tumor is to completely excise the tumor in the periadventitial plane with the patient under general anesthesia, thereby preserving the continuity of the carotid artery [7, 9]. Clamping of the main carotid artery may be needed if a serious hemorrhage occurs during the operation. The risk for neurological damage is very low if the duration of clamping is less than 10 minutes [10, 11]. Invasion of vascular tissues and neural structures makes the surgery difficult, although the results obtained by experienced centers are satisfactory. When the tumor is removed, the internal carotid should be protected; if it is injured or cut, it should be repaired with saphenous vein or synthetic graft. Control of the internal carotid artery pulse and the measurement of the flow with a flowmeter, if available, are important modalities that can be used to prevent possible cerebral complications. A flowmeter is a simple, inexpensive, noninvasive, and repeatable measurement method without side effects. In addition, it does not require the use of a contrast agent, which is beneficial for a radiation-free working environment. It does not require experienced staff members for use, and its measurements can be performed in a minimal amount of time (i.e., 3 to 4 minutes). The flowmeter eliminates all of the potential problems associated with Doppler and electromagnetic techniques. It can be used to make an assessment without the need for technical calibration and with no concern for angle or diameter unsuitability. Transit-time flow measurement involves the principle that the moving velocity of ultrasound waves in the direction and opposite direction of flow are different [12]. For our patient, we measured the flows with a flowmeter because her carotid pulse was poor after tumor removal, and there was kinking of the artery. We performed patch plasty with the saphenous vein due to poor flow in the internal carotid artery.

In conclusion, vascular surgery for the treatment of carotid body tumors can be performed using advanced technical facilities and devices with acceptable morbidity and mortality rates. Complications that may render treatment impossible can develop with the growth of the tumor. Devices such as the flowmeter must be used as much as possible during these operations.

**Conflict of interest statement:** The authors declare that they have no conflict of interest to the publication of this article.

## References

1. Lack EE, Cubilla AL, Woodruff JM, Farr HW. Paragangliomas of the head and neck region: A clinical study of 69 patients. *Cancer* 1977; 39: 397-409. [\[CrossRef\]](#)
2. Hallett JW Jr, Nora JD, Hollier LH, Cherry KJ Jr, Pairolero PC. Trends in neurovascular complications of surgical management for carotid body and cervical paragangliomas: A fifty-year experience with 153 tumors. *J Vasc Surg* 1988; 7: 284-91. [\[CrossRef\]](#)
3. Nora JD, Hallett JW Jr, O'Brien PC, Naessens JM, Cherry KJ Jr, Pairolero PC. Surgical resection of carotid body tumors: long-term survival, recurrence, and metastasis. *Mayo Clin Proc* 1988; 63: 348-52.
4. van der Mey AG, Jansen JC, van Baalen JM. Management of carotid body tumors. *Otolaryngol Clin North Am* 2001; 34: 907-24. [\[CrossRef\]](#)
5. Plukker JT, Brongers EP, Vermey A, Krikke A, van den Dungen JJ. Outcome of surgical treatment for carotid body paraganglioma. *Br J Surg* 2001; 88: 1382-6. [\[CrossRef\]](#)
6. Gaylis H, Davidge-Pitts K, Pantanowitz D. Carotid body tumours. A review of 52 cases. *S Afr Med J* 1987; 72: 493-6.
7. Matticari S, Credi G, Pratesi C, Bertini D. Diagnosis and surgical treatment of the carotid body tumors. *J Cardiovasc Surg (Torino)* 1995; 36: 233-9.
8. Luna-Ortiz K, Rascon-Ortiz M et al. Does Shamblin's classification predict postoperative morbidity in carotid body tumors? A proposal to modify Shamblin's classification. *Eur Arch Otorhinolaryngol* 2006; 263: 171-5. [\[CrossRef\]](#)
9. Ünlü Y, Azman A, Özyazıcıoğlu A, et al. Carotid body tumours (Paragangliomas). *Asian Cardiovasc Thorac Surg* 2001; 3: 208-11.
10. Dağlar B, Kırallı K, Akıncı E, et al. Carotid body tumor. *Koşuyolu Heart* 1997; 2: 182-9.
11. Baçgel F, Özcan C, Baçgel K, ve ark. Bir Carotid Body Tümörü Olgusu. *Damar Cer Derg.* 1999; 8: 88-91.
12. Sanisoglu I, Guden M, Balci C, Sagbas E, Duran C, Akpınar B. Comparison of intraoperative transit-time flow measurement with early postoperative magnetic resonance flow mapping in off-pump coronary artery surgery. *Tex Heart Inst J* 2003; 30: 31-7.