

Efficiency of Hyperbaric Oxygen Therapy in the Treatment of Carbon Monoxide Toxicity

Karbon Monoksit Zehirlenmesinin Tedavisinde Hiperbarik Oksijen Terapisinin Etkinliği

Recep Hormova¹, Gokhan Polat²



¹Department of Underwater and Hyperbaric Medicine, Atatürk University School of Medicine, Erzurum, Turkey

²Department of Radiology, Atatürk University School of Medicine, Erzurum, Turkey

Received: February 6, 2017
Accepted: February 12, 2017
Available Online Date: April 28, 2017

Correspondence to: Gokhan Polat

E-mail: dr.g.polat@gmail.com

DOI 10.5152/eurasianjmed.2017.17035

©Copyright 2017 by the Atatürk University School of Medicine - Available online at www.eurasianjmed.com

A 41-year-old male presented with carbon monoxide (CO) exposure. The patient's Glasgow Coma Scale (GCS) score was 9. Dual-energy CT (DECT) revealed a perfusion defect on the bilateral globus pallidus (Figure 1a). The patient was intubated and immediately underwent hyperbaric oxygen therapy (HBOT). In addition to normobaric oxygen therapy, two sessions on the first day and one session each on the second, third, and fourth days of HBOT were performed. DECT was performed on the fifth day of hospitalization after HBOT was completed. Control DECT showed a decrease in iodine uptake and relative recovery in perfusion in the bilateral globus pallidus (Figure 1b). After HBOT sessions, the following results were observed: GCS: before treatment, 9 and after treatment, 15; COHb level: before treatment, 55.1% and after treatment, 5.3%; MetHb level: before treatment, 1.9% and after treatment, 1.1%.

CO prevents hemoglobin binding to oxygen. Thus, CO causes hypoxia in tissues. The brain needs more oxygen than other tissues. For this reason, the brain is considerably affected by hypoxia [1]. An iodine map is effective for revealing contrast differences among tissues [2]. DECT can be used following damage to the brain and treatment [1]. HBOT is an effective procedure for treating CO toxicity. It plays an important role in improving the radiological and clinical findings of patients [1]. These findings proved that HBOT is a very important, successful and effective in the treatment of CO intoxication if used at the right time.

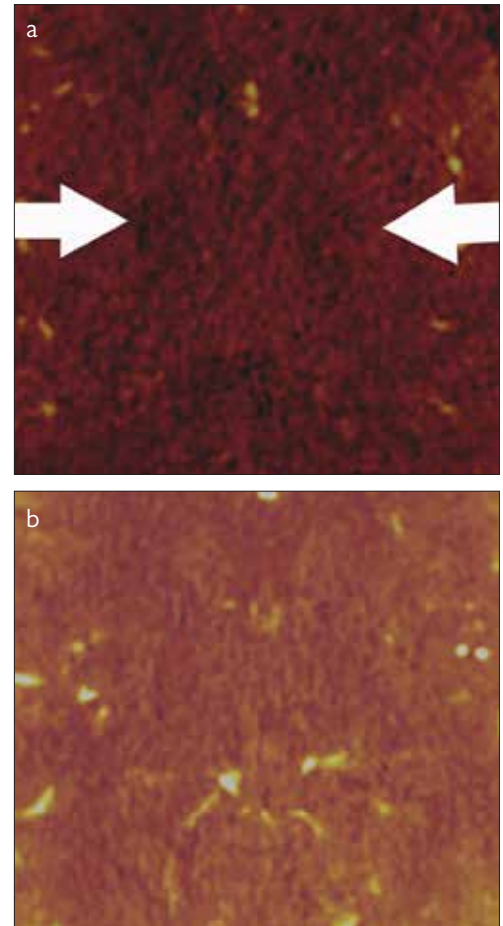


Figure 1. a, b. Dual-energy CT (DECT) revealed a perfusion defect on the bilateral globus pallidus (Arrows) (a). Control DECT showed a decrease in iodine uptake and relative recovery in perfusion in the bilateral globus pallidus (b).

Peer-review: Externally peer-reviewed.

Author Contributions: Concept - R.H., G.P.; Design - R.H., G.P.; Supervision - R.H., G.P.; Resources - R.H., G.P.; Materials - R.H., G.P.; Data Collection and/or Processing - R.H., G.P.; Analysis and/or Interpretation - R.H., G.P.; Literature Search - R.H., G.P.; Writing - R.H., G.P.; Critical Review - R.H., G.P.

Conflict of Interest: No conflict of interest was declared by the authors.

Financial Disclosure: The authors declared that this study has received no financial support.

References

1. Uzkeser M, Kocak AO, Akbas I, et al. Dual-energy CT shows brain ischemia and hyperbaric oxygen therapy efficacy in acute CO intoxication. *Am J Emerg Med* 2016; 34: 1327. [\[CrossRef\]](#)
2. Pirimoglu B, Sade R, Ogul H, Kantarci M, Eren S, Levent A. How can new imaging modalities help in the practice of radiology? *Eurasian J Med* 2016; 48: 213-21. [\[CrossRef\]](#)