

Right Ventricular Outflow Tract Tachycardia: a Common Rhythm due to an Uncommon Etiology

Berhan Pirimoglu¹ , Alper Duran² , Cihan Duran² 



Cite this article as: Pirimoglu B, Duran A, Duran C. Right ventricular outflow tract tachycardia: A common rhythm due to an uncommon etiology. *Eurasian J Med* 2018; 50: DOI: 10.5152/eurasianjmed.2018.18138.

ORCID IDs of the authors:
B.P.: 0000-0002-1608-1189
A.D.: 0000-0003-0420-0344
C.D.: 0000-0002-3376-3210

¹Department of Radiology, Atatürk University School of Medicine, Erzurum, Turkey
²Department of Radiology, University of Texas Medical Branch, Houston, United States

Received: April 11, 2018
Accepted: April 19, 2018
Available Online Date: December 3, 2018

Correspondence to: Berhan Pirimoglu
E-mail: berhan.dr@gmail.com

DOI 10.5152/eurasianjmed.2018.18138

©Copyright 2018 by the Atatürk University School of Medicine - Available online at www.eurasianjmed.com

ABSTRACT

Right ventricular outflow tract (RVOT) aneurysm is a rare cause of RVOT ventricular tachycardia (RVOT-VT). We present a very unusual case of RVOT-VT due to an RVOT aneurysm diagnosed by cardiovascular magnetic resonance imaging.

Keywords: Right ventricular outflow tract, aneurysm, cardiac MRI

Introduction

Right ventricular outflow tract ventricular tachycardia (RVOT-VT) is a type of monomorphic ventricular tachycardia originating from RVOT or usually from tricuspid annulus. The characteristic morphology of RVOT-VT is a wide QRS complex tachycardia with the left bundle branch block (LBBB) pattern and an inferior axis approximately +90 degrees. The RVOT-VT occasionally occurs in patients without an underlying structural heart disease, although it may also be related to focal anatomical and wall motion abnormalities. These abnormalities of the RVOT include wall thinning, presence of the fatty fibrous tissue (context of arrhythmogenic right ventricular dysplasia), and aneurysms [1-5].

The RVOT aneurysms usually occur after a surgical intervention such as the repair of the tetralogy of Fallot [6-8]. Snyder et al. [8] analyzed 53 patients with a following tetralogy of Fallot repair. They found the RVOT aneurysm in 49 out of 53 patients. Occasionally, the RVOT aneurysms may rarely occur as an unusual reason of the RVOT tachycardia in adult patients [9-11]. These aneurysms are best seen on the cardiovascular magnetic resonance imaging (CMRI) and frequently missed by other imaging modalities such as echocardiography or electrophysiological study. Thus, cine CMRI is a reliable and noninvasive technique in the diagnosis of RVOT aneurysms as a cause of the RVOT-VT. The CMRI is very useful to describe the characteristics of the right ventricle myostructure and functional changes in patients with RVOT-VT [3, 10].

Herein, we report an adult case of the RVOT aneurysm as an unusual cause of RVOT-VT with CMRI findings.

Case Presentation

A 61-year-old female without known coronary artery disease presented to hospital with palpitations and severe chest pain. A surface electrocardiogram (ECG) demonstrated wide complex tachycardia (220 beats/min) of LBBB morphology with an inferior axis, suggesting a RVOT origin. She was cardio-verted at the emergency clinic. As part of the workup, a CMRI was obtained, including a dedicated and comprehensive wall motion analysis delayed-enhancement imaging (DE) of the left and right ventricles after 0.2 mmol/kg of the contrast agent management. Signed informed consent was obtained.

Both the left and right ventricles were normal in size and function. However, in the RVOT, a focal aneurysmal dilation with dyskinesia was present, measuring 3.7x3.5x3.4 cm, located immediately below the pulmonic valve (Figure 1). The cine CMRI studies identified the aneurysm more significantly (Video 1). In the DE sequence, no obvious hyperenhancement was identified, likely due

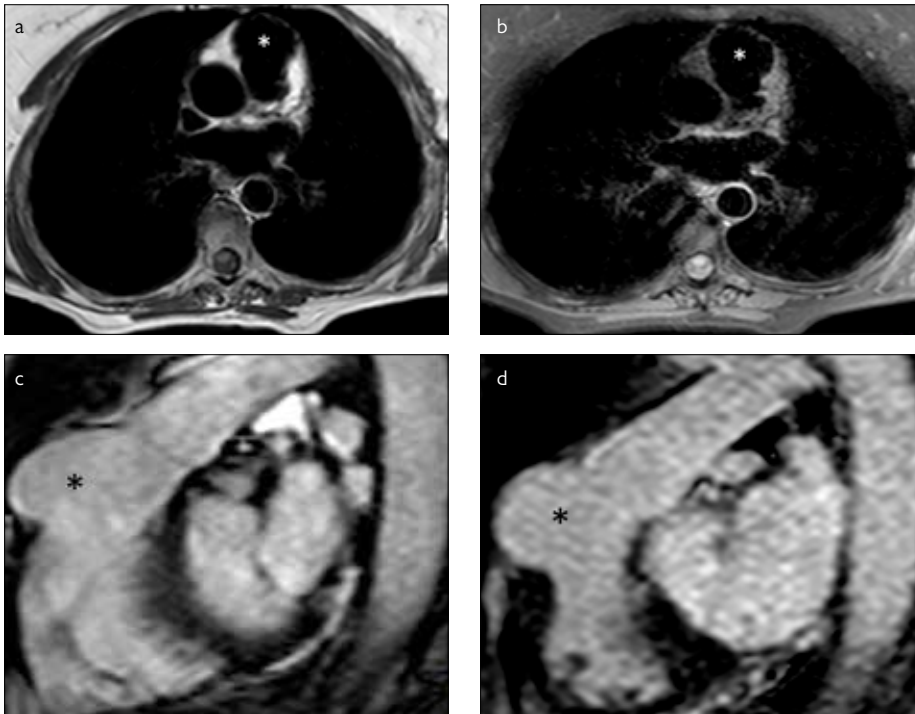


Figure 1. a-d. Axial T1-weighted (SEEP) image (a) and axial fat sat T2-weighted (SEEP) image (b) show the RVOT aneurysm (white asterisks). Sagittal T1-weighted contrast enhanced images (c, d) show the RVOT aneurysm (black asterisks). SEEP: Spin echo eco planar imaging. RVOT: Right ventricle outflow tract.

to the thinned wall and limited spatial resolution of the imaging sequence.

The catheter coronary angiography was also performed to confirm the RVOT aneurysm (Video 2). At the electrophysiological study, a VT of similar morphology was induced in the anterior septal site of RVOT. It was successfully ablated using a 4 mm ablation (ThermoCool RMT) catheter.

Discussion

Of all outflow tract tachycardias, the RVOT-VT is the most common. It may result in recurrent symptoms of palpitations and dizziness and, less commonly, a loss of consciousness. The RVOT-VT are not considered life-threatening [12, 13].

The RVOT-VT are commonly triggered by sympathetic stimulation, such as anxiety and excitement. In addition, stimulants such as caffeine seem to play a provocative role. In pre-menopausal women, hormonal influences may also seem to play a significant role. Fewer than 20% of patients are asymptomatic, receiving an incidental diagnosis after undergoing ECG during a routine physical examination [13, 14].

Echocardiography is the first step in some patients, including CMRI with delayed enhancement. It is particularly important to exclude the mild forms of ARVD. The CMRI reveals mild

structural abnormalities of the right ventricle in patients with RVOT-VT, primarily involving wall thinning, fatty infiltration, motion abnormalities, and aneurysms [1, 15, 16]. Kunze et al. determined RVOT aneurysms by cine angiography in 4 of 11 patients with RVOT ventricular tachycardia [11]. In another study, Globits et al. detected a focal aneurysm in 1 patient, including focal or general wall thinning in 9 patients with recurrent episodes of symptomatic RVOT tachycardia [9].

Anatomic knowledge of the RVOT can help one understand the etiology of symptomatic RVOT tachycardia [14-16]. A study by Carlson et al. that included patients with RVOT showed the ability of MRI to demonstrate subtle structural abnormalities of the right ventricle more often than other imaging techniques, such as echocardiography and angiography [10]. CMRI is an excellent noninvasive imaging modality for the right ventricle morphology, function analysis, and when serial monitoring is necessary for a systemic right ventricle evaluation. It can also be repeated [16]. In patients with a pacemaker, computed tomography (CT) could be good choice for the evaluation of RVOT [17]. But the temporal resolution of CT is not as fast as the resolution with CMRI. A comprehensive anatomical and functional evaluation of the right ventricle may necessitate the CMRI quantitative values such as the stroke volume, ejection fraction, or when sustaining the RVOT abnor-

malty is suspected on cine images [15, 18]. In our case, we detected the aneurysmal dilatation that was dyskinetic and had a thin wall at the level of the RVOT below the pulmonary valve in various cine images, but we obtained normal quantitative values of the right ventricle. Thus, we determined the site of the right ventricular tachycardia via CMRI examinations.

For treatment of the RVOT aneurysms, a catheter ablation has a high acute success rate of up to 90%, but recurrences are common. Novel different catheter designs and ablation technologies aim to improve the procedural outcome and increase the long-term success rate [19, 20]. By now, it has usually been used in ablation of supraventricular tachycardia, mainly atrial fibrillation. But recently, it has been used for RVOT tachycardia and ventricular premature beats [21]. Our patient also underwent catheter ablation for the treatment of the RVOT aneurysm. The sinus rhythm occurred, and there was no complications during the ablation procedure.

The RVOT aneurysm is one of the rare causes of the outflow tract tachycardia. The CMRI has become the ideal method for an anatomic evaluation of the RVOT and for diagnosis of abnormalities from this challenging field. The correct diagnosis of these aneurysms is required for a definitive treatment planning.

Informed Consent: Informed consent was obtained from the patient.

Peer-review: Externally peer-reviewed.

Author Contributions: Concept – C.D.; Design – B.P., C.D.; Supervision – C.D., A.D.; Materials – C.D.; Data Collection and/or Processing – C.D.; Analysis and/or Interpretation – B.P.; Literature Search – A.D.; Writing Manuscript – B.P.; Critical Review – C.D.

Conflict of Interest: The authors declared no conflicts of interest.

Financial Disclosure: The authors declared that this study has received no financial support.

Video 1. The RVOT (right ventricle outflow tract) aneurysm is seen in the cine T1-weighted coronal contrast-enhanced image series.

Video 2. The RVOT (right ventricle outflow tract) aneurysm is determined by right ventricle angiography image series.

References

- Lerman B, Stein KM, Markowitz SM, Mittal S, Slotwiner DJ. Right Ventricular Outflow Tract Tachycardia: An Update. *Card Electrophysiol Rev* 2002; 6: 68-71. [\[CrossRef\]](#)

2. Gangadharan V, Sharma D, Ramu V, Paul T. Too Much Exercise: Right Ventricular Outflow Tract Tachycardia. *Am J Med* 2014; 127: 205-8. [\[CrossRef\]](#)
3. Globits S, Kreiner G, Frank H, et al. Significance of Morphological Abnormalities Detected by MRI in Patients Undergoing Successful Ablation of Right Ventricular Outflow Tract Tachycardia. *Circulation* 1997; 96: 2633-40. [\[CrossRef\]](#)
4. Valk SD, de Groot NM, Szili-Torok T, Van Belle YL, Res JC, Jordaens L. Clinical characteristics and acute results of catheter ablation for outflow tract ventricular tachycardia or premature beats. *J Interv Card Electrophysiol* 2012; 35: 301-09. [\[CrossRef\]](#)
5. Ventura R, Steven D, Klemm HU, et al. Decennial follow-up inpatients with recurrent tachycardia originating from the right ventricular outflow tract: electrophysiologic characteristics and response to treatment. *Eur Heart J* 2007; 28: 2338-45. [\[CrossRef\]](#)
6. Welch E, Zabaleta I, Fojaco R, Perryman R. Aneurysm of the right ventricular outflow tract: a complication of aorta-main pulmonary (central) shunt. *Pediatr Cardiol* 1991; 12: 229-32. [\[CrossRef\]](#)
7. Inoue Y, Igawa O, Iitsuka K. Aneurysm of the right ventricular outflow tract after surgical repair of Tetralogy of Fallot: three-dimensional computed tomography findings. *Europace* 2009; 11: 130. [\[CrossRef\]](#)
8. Snyder MS, Levin AR, Engle MA. Right Ventricular Outflow Tract Aneurysm Following Tetralogy of Fallot Repair. *Pediatric Research* 1987; 21: 195A.
9. Globits S, Kreiner G, Frank H, et al. Significance of morphological abnormalities detected by MRI in patients undergoing successful ablation of right ventricular outflow tract tachycardia. *Circulation* 1997; 96: 2633-40. [\[CrossRef\]](#)
10. Carlson MD, White RD, Trohman RG, et al. Right ventricular outflow tract ventricular tachycardia: detection of previously unrecognized anatomic abnormalities using cine magnetic resonance imaging. *J Am Coll Cardiol* 1994; 24: 720-7. [\[CrossRef\]](#)
11. Kunze KP, Hoifman M, Kuck KH. A prospective study of intravenous and oral flecainide in right ventricular arrhythmia. *J Am Coll Cardiol* 1988; 11: 56A.
12. Buxton AE, Waxman HL, Marchlinski FE, Simson MB, Cassidy D, Josephson ME. Right ventricular tachycardia: clinical and electrophysiologic characteristics. *Circulation* 1983; 68: 917-927. [\[CrossRef\]](#)
13. Srivathsan K, Lester SJ, Appleton CP, Scott LR, Munger TM. Ventricular tachycardia in the absence of structural heart disease. *Indian Pacing Electrophysiol J* 2005; 5: 106-121.
14. Nakagawa M, Takahashi N, Nobe S, et al. Gender differences in various types of idiopathic ventricular tachycardia. *J Cardiovasc Electrophysiol* 2002; 13: 633-638. [\[CrossRef\]](#)
15. Geva T, Powell AJ, Crawford EC, Chung T, Colan SD. Evaluation of regional differences in right ventricular systolic function by acoustic quantification echocardiography and cine magnetic resonance imaging. *Circulation* 1998; 98: 339-345. [\[CrossRef\]](#)
16. Saremi F, Ho SY, Cabrera JA, Sánchez-Quintana D. Right ventricular outflow tract imaging with CT and MRI: Part 1, Morphology. *AJR Am J Roentgenol* 2013; 200: 39-50. [\[CrossRef\]](#)
17. Nance JW Jr, Bastarrika G, Kang DK, et al. High-temporal-resolution dual-energy computed tomography of the heart using a novel hybrid image reconstruction algorithm: initial experience. *J Comput Assist Tomogr* 2011; 35: 119-125. [\[CrossRef\]](#)
18. Pirimoglu B, Sade R, Ogul H, Kantarci M, Eren S, Levent A. How Can New Imaging Modalities Help in the Practice of Radiology? *Eurasian J Med* 2016; 48: 213-221.
19. Valk SD, de Groot NM, Szili-Torok T, Van Belle YL, Res JC, Jordaens L. Clinical characteristics and acute results of catheter ablation for outflow tract ventricular tachycardia or premature beats. *J Interv Card Electrophysiol* 2012; 35: 301-09. [\[CrossRef\]](#)
20. Ventura R, Steven D, Klemm HU, et al. Decennial follow-up inpatients with recurrent tachycardia originating from the right ventricular outflow tract: electrophysiologic characteristics and response to treatment. *Eur Heart J* 2007; 28: 2338-45. [\[CrossRef\]](#)
21. Valk SD, de Groot NM, Jordaens L. Catheter ablation of right ventricular outflow tract tachycardia using contact force guidance. *Neth Heart J* 2014; 22: 460-2. [\[CrossRef\]](#)