

# Evaluating Ossifications of the Nuchal Ligament with Cervical Computed Tomography

Erkan Gokce<sup>1</sup> , Murat Beyhan<sup>2</sup> 



*Cite this article as:* Gokce E, Beyhan M. Evaluating Ossifications of the Nuchal Ligament with Cervical Computed Tomography. *Eurasian J Med* 2018; 23-7.

<sup>1</sup>Department of Radiology, Medicine School, Gaziosmanpaşa University, Tokat, Turkey

<sup>2</sup>Department of Radiology, Tokat State Hospital, Tokat, Turkey

Received: October 28, 2017

Accepted: December 23, 2017

Correspondence to: Erkan Gokce  
E-mail: drerkangokce@gmail.com

DOI 10.5152/eurasianjmed.2018.17314

©Copyright 2018 by the Atatürk University School of Medicine - Available online at [www.eurasianjmed.com](http://www.eurasianjmed.com)

## ABSTRACT

**Objective:** The nuchal ligament (NL) extends from the external occipital protuberance and median nuchal line to the spinous process of the 7th cervical vertebrae. In this study, we evaluated the incidence, location level, and size of ossifications of the NL (ONL) in patients who underwent cervical computed tomography (CT) for various reasons.

**Materials and Methods:** The present study included 481 patients (187 females and 294 males) who underwent cervical CT from February 2011 to November 2016 due to reasons such as trauma, cervical spondylosis, neck pain, and screening for metastasis. CT was performed using 2- or 8-slice scanners. Archive images of patients on picture archiving and communication system were retrospectively evaluated by two radiologists. The structures in bone density and form detected in NL were evaluated as nuchal ossification. ONL location levels, numbers, and dimensions were determined. The relationship between both sexes and age and the incidence of ONL was investigated.

**Results:** ONL was detected in 44 patients (9.14%). The mean ages of patients with ONL and without ONL were  $62.27 \pm 13.92$  (23–86) and  $41.78 \pm 20.76$  (4–101) years, respectively. There was a statistically significant relationship between ONL and age ( $p < 0.001$ ). Thirty-six patients had one ONL, seven patients had two, and one patient had three. The most common ONL location was the C5 spinous process level ( $n=12$ ) followed by the C6 spinous process level ( $n=8$ ). The longest ONL in craniocaudal direction was 20.9 mm, and the shortest one was 3.1 mm.

**Conclusion:** ONL is a smooth-contoured ovoid or round bone structure extending parallel to the longitudinal axis that can frequently be observed as one or multiple occurrences with different sizes on cervical CT images.

**Keywords:** Cervical spine, computed tomography, ossification of nuchal ligament, spinous process

## Introduction

The nuchal ligament (NL) is an intervertebral syndesmosis that extends from the external occipital protuberance and median nuchal line to the spinous process of the 7th cervical vertebra. It is a bilaminar fibroelastic intermuscular septum interposed between the paravertebral muscle pairs of the cerviconuchal region [1]. It consists of the lamellar and funicular parts. The lamellar part is a bilayer structure and is difficult to distinguish from the interspinous ligament. The funicular part, on the other hand, is fibrous and formed by the fusion of lamellar layer in posterior [1]. NL contributes to the stabilization of the head during cervical spine movement and maintenance of the lordotic sequence [1-4]. Focal ossifications (sesamoid bones) of different etiologies can develop in the NL. Ossifications of the NL (ONLs) appear as well-bordered, regularly shaped bone structures whose center contains bone marrow and whose periphery is surrounded by cortical bone in computed tomography (CT) images [3]. Entities such as myositis ossificans, clay-shoveler's fracture, calcinosis circumscripta, calcareous bursitis, nuchal fibrocartilaginous pseudotumor, heterotrophy in the secondary nucleus of the C6 spinous process, calcific tendinitis or calcium hydroxyapatite disease, fluoride poisoning, surgical trauma, sarcoidosis, amyloidosis, systemic lupus erythematosus, hyperparathyroidism, and burns calcifications should be considered in the differential diagnosis of nuchal sesamoid bone [3, 5-8]. In the present study, ONL was evaluated in patients who underwent cervical CT examinations mainly due to trauma and other reasons such as cervical spondylosis, neck pain, and screening for metastasis.

## Material and Methods

This retrospective study was approved by our institutional ethics committee, and informed consent was waived. There were 481 participants (187 females and 294 males) out of 505 patients who underwent cervical CT examinations at the Radiology Department of Gaziosmanpaşa University Medical School from February 2011 to November 2016. Patient images were randomly selected from the picture archiving and communication system (PACS), and patients whose vertebral bony structures and paravertebral soft tissue integrity were preserved were included. Postoperative patients (n=11) and patients with spinous process or multiple vertebral fractures (n=9), and multiple congenital anomalies (n=4) were excluded (total=24 patients). CT examinations were performed using 2-slice (Somatom Sprit; Siemens, Erlangen, Germany) or 8-slice CT scanners (LightSpeed Ultra; GE, Milwaukee, USA). CT examinations were performed with helical scanning, and the axial plane was obtained with a cross-sectional thickness of 2–3 mm and the B31s, B40s, or B60s kernels. CT examinations were evaluated on bone windows (window level: 300, window width: 2000) on sagittal and coronal reformat images obtained with axial sections and 1–3-mm reconstruction interval. Archive images of patients on PACS were retrospectively evaluated by two radiologists. Examinations and measurements were simultaneously performed by two radiologists, and ONL was diagnosed with consensus. Well-bordered, regularly shaped bone structures whose centers contained bone marrow and whose periphery was surrounded by cortical bone in NL observed with CT were considered ONL. ONL location levels, numbers, and dimensions were determined. The dimensions were evaluated in the craniocaudal, anteroposterior, and mediolateral directions.

### Statistical analysis

Descriptive statistics were expressed as the mean±standard deviation (range). Chi-squared tests were performed for comparisons of categorical variables between groups. Independent-samples t-test was used to compare the means of two groups. A p-value of <0.05 was considered significant. Statistical analysis was performed using the Statistical Package for Social Sciences 18.0 software (IBM Corp.; Armonk, NY, USA).

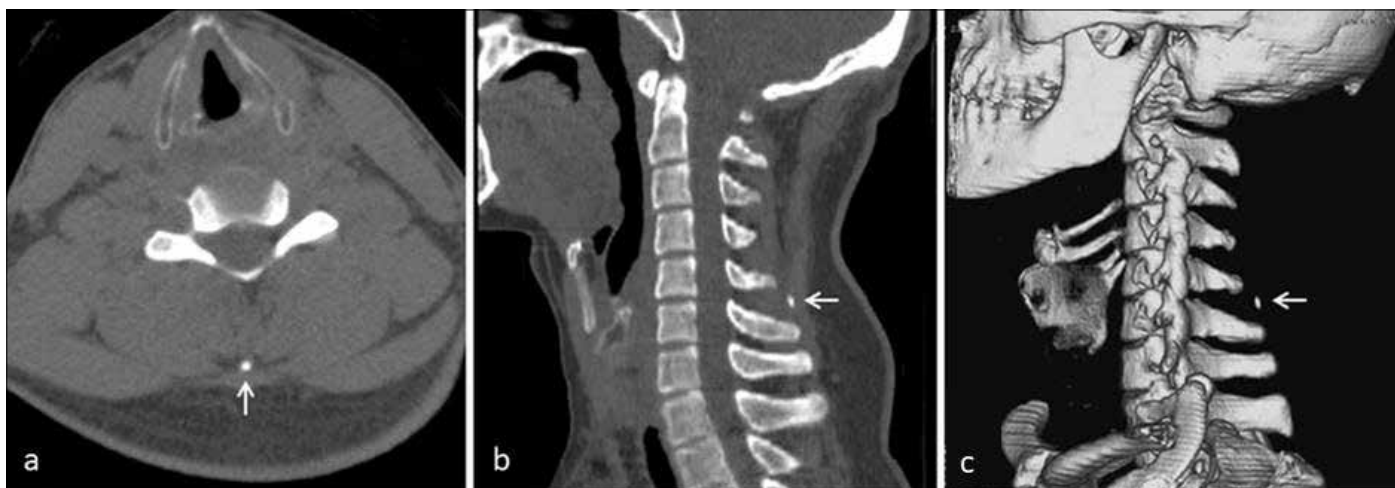
### Result

The mean age of all patients was 43.65±21.07 (4–101) years. The reasons for radiological imaging of patients were trauma (n=458,

**Table 1.** Demographic features of patients, reasons for radiological examination, ossifications of the nuchal ligament detection level, and dimensions of the nuchal ligament ossifications

Patient No	Sex	Age	Localizations	Dimensions (mm)	Reason for Examination
1	F	79	C5 spinous process	3.1×2.2×3.1	trauma
2	M	72	C4 spinous process	7.1×4.5×4.3	trauma
3	M	71	C5 spinous process	6×2.1×1.7	trauma
4	M	65	C5 spinous process	10.2×4.1×4.2	hernia
5	M	58	C5–6 disk space	5.3×3×2	spondylosis
6	M	43	C5 spinous process	6×3×3	trauma
7	F	86	C7 spinous process	5.8×3.7×7.5	trauma
8	F	55	C6 spinous process	8×2.9×1.6	trauma
9	F	72	C5 spinous process	9.6×5.6×4.5	trauma
10	M	66	C5 spinous process	8.7×4.7×4.1	spondylosis
11	M	62	C6 spinous process	7.8×3.8×3.1	trauma
12	M	63	C4–C6 disk space	20.9×9×8.3	trauma
13	M	74	C4–C5 disk space	8.9×3.5×3.3	spinal stenosis
14	M	78	C4–5 disk space	12.6×9.6×11.8	trauma
			C4–5 disk space	11.5×7.1×8.5	
15	M	70	C4 spinous process	7.6×2.4×3.2	trauma
16	F	70	C4–5 disk space	15×6×3.5	trauma
17	M	68	C3–5 disk space	15×3.3×3.7	trauma
			C6 spinous process	6×4.2×4.5	
18	M	67	C5–6 disk space	8.2×8.5×20.2	trauma
19	F	49	C6 spinous process	8.7×3.9×3.6	trauma
20	M	76	C4–5 disk space	14.2×7.4×9.4	
			C6 spinous process	9.1×8.2×5.1	trauma
21	M	74	C5 spinous process	9.3×4.9×4.3	
			C5 spinous process	3.9×3.8×4.3	trauma
22	M	62	C4–5 disk space	13.4×5.9×4.4	trauma
23	M	68	C5 spinous process	3.3×11.3×5	trauma
24	F	59	C4–5 disk space	10.4×3.1×2.4	
			C5–6 disk space	3.6×4×8.5	trauma
25	F	71	C6 spinous process	3.7×2.8×6	trauma
26	F	70	C4–5 disk space	14.9×6.5×4.8	trauma
27	M	50	C4 spinous process	6.9×5×4.2	trauma
28	M	70	C7 spinous process	11.7×3.6×4.8	trauma
29	M	48	C5 spinous process	8.2×3.8×3.1	trauma
30	F	62	C5 spinous process	7×2×2.2	trauma
31	F	37	C6 spinous process	7.5×4.1×3.8	trauma
32	M	64	C3–4 disk space	13×4.8×4.2	
			C4–5 disk space	11×5×5.6	trauma
33	M	27	C6 spinous process	4.3×2.2×1.1	trauma
34	M	39	C5–6 disk space	8.5×6.1×4.4	trauma
35	M	62	C5 spinous process	9.6×3.4×3.5	trauma
36	M	55	C5 spinous process	10.9×6×5.5	trauma
37	M	48	C6 spinous process	8.2×5×3.9	trauma
38	M	72	C3–4 disk space	12.1×6.1×8.1	trauma
39	M	23	C5–6 disk space	6.5×3.2×2.5	trauma
40	M	76	C3–4 disk space	8.5×4.3×6.5	
			C4–5 disk space	8.5×6.5×2.1	trauma
41	F	73	C6 spinous process	9.1×6.1×5	trauma
42	M	46	C3 spinous process	3.2×3.8×1.7	
			C4 spinous process	4.8×7.9×6.9	
			C5 spinous process	5.4×3.9×6.5	trauma
43	M	63	C4–6 disk space	16.4×8.5×5.6	
			C6–7 disc space	5.2×5.6×4.7	trauma
44	M	77	C7 spinous process	12×3.9×7.8	trauma

F: female; M: male

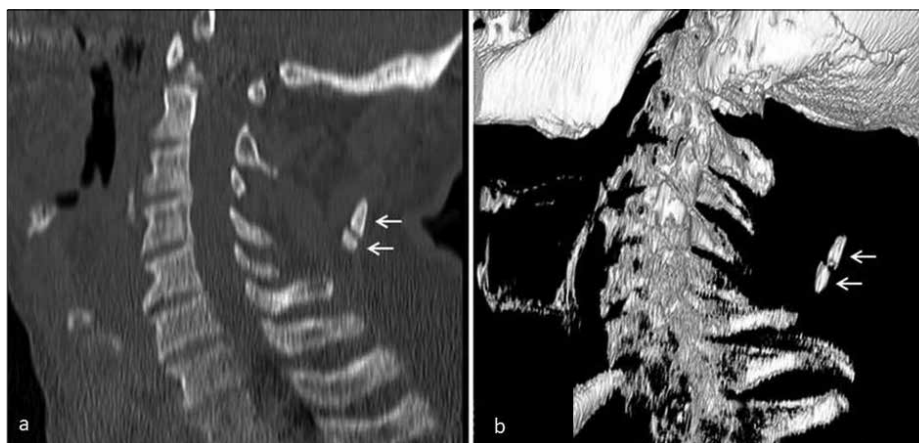


**Figure 1. a-c.** Axial (a), sagittal reformatted (b), and volume rendering (c). CT images show a small nuchal sesamoid bone (arrow) in the C5–6 disk interval level of a 23-year-old patient who underwent cervical CT due to trauma

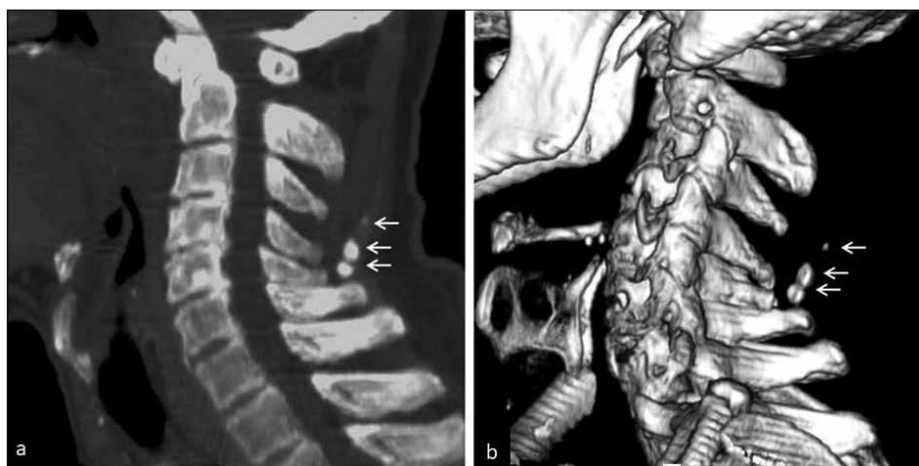
90.6%), cervical disk hernia (n=11, 2.28%), spondylosis (n=10, 2.07%), scoliosis (n=5, 1.03%), metastasis screening (n=2, 0.41%), spinal stenosis (n=1, 0.20%), and ankylosing spondylitis (n=1, 0.20%). ONL was detected in 44 patients (9.1%). The mean age of patients with ONL was  $62.27 \pm 13.92$  (23–86) years. The mean age of patients without ONL was  $41.78 \pm 20.76$  (4–101) years. There was a statistically significant relationship between ONL and age ( $p < 0.001$ ). Thirty-three of the patients (75%) with ONL were male, and 11 (25%) were female. Of the patients without ONL, 261 (59.7%) were male and 176 (40.3%) were female. There was a statistically significant correlation between sexes for ONL incidence ( $p = 0.048$ ). A total of 54 ONLs were detected in 44 patients; 36 patients had one ONL (Figure 1), 7 patients had two (Figure 2), and 1 patient had three (Figure 3). ONL was most common in the C5 spinous process (n=12, 27.2%), followed by the C6 spinous process (n=8, 18.1%). No ONL was detected in the cranial of C3 spinous process level. Measured average ONL dimensions were  $9.35 \pm 3.85$  (3.1–20.9) mm in the craniocaudal direction,  $4.77 \pm 1.89$  (2.0–9.6) mm in the anteroposterior direction, and  $4.56 \pm 2.14$  (1.1–11.8) mm in the mediolateral direction (Figure 4). Demographic features of all patients, reasons for radiological examination, ONL location level, numbers, and dimensions of ONL are given in Table 1. Distribution of patients with ONL and patients without ONL by age are given in Table 2.

## Discussion

Ossifications of the NL are generally asymptomatic and can be coincidentally detected in lateral cervical radiographs. They are generally smoothly contoured, ovoid, or round bone structures extending parallel to the longitudinal



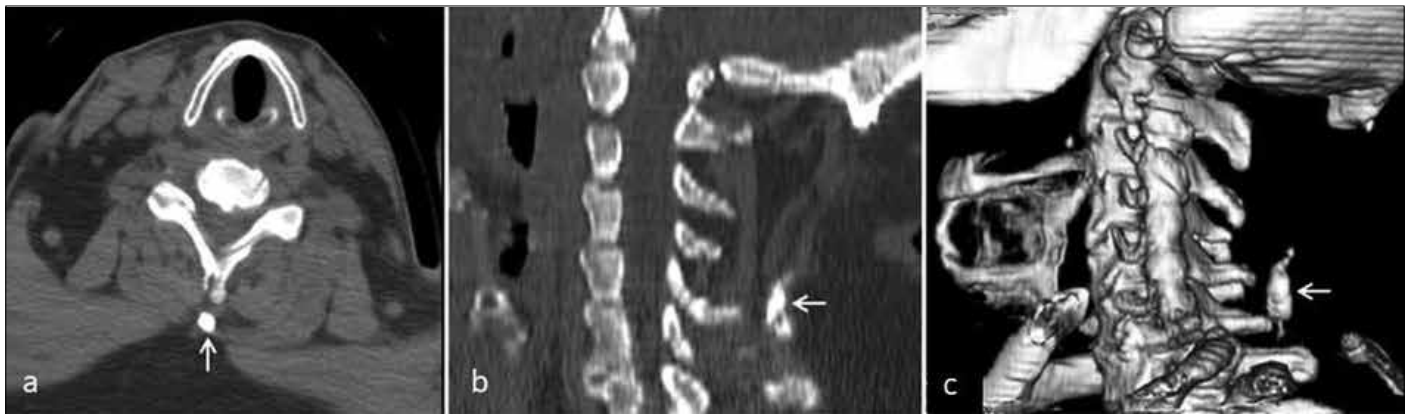**Figure 2. a, b.** Sagittal reformatted (a) and volume rendering (b). CT images show two nuchal bones (arrows) in the C3–4 and C4–5 levels of a 64-year-old male patient who underwent cervical CT because of trauma



**Figure 3. a, b.** Sagittal reformatted (a) and volume rendering (b). CT images show three nuchal sesamoid bones (arrows) of a 46-year-old male patient in the C3, C4, and C5 spinous process levels. CT was taken due to trauma

axis [2, 3]. They are predominantly found as a single bone [2, 3]. In Scapinelli's study, one ONL was detected in 82% of the patients, whereas two ONLs were detected in 18% [9].

In the present study, single and two bones were detected in 81.81% and 15.90% of the patients, respectively. In the study by Scapinelli [9], ONL was detected in no more than two bones,



**Figure 4. a-c.** Axial (a), sagittal reformatted (b), and volume rendering (c). CT images show amorphous and the longest nuchal sesamoid bone (arrows) in the C4–6 spinous process level of a 63-year-old male patient who underwent CT due to trauma

whereas in our study, 1 patient (2.27%) was found to have three ONLs.

The most common locations of ONL are C5–6 and C6–7 levels [2, 3]. The most common level for nuchal ossifications in the present study was the C5–C6 level with 25 bones (46.29%). Mechanical factors and repeating traumas are considered to be responsible for the pathogenesis of ONL development [2, 3]. Forward flexion of the neck results in pressure in NL against the apex of spinous processes and leads to the formation of ossicles at higher mobility region, that is, the C5–C6 level [3, 9]. The fact that ONL is most common in the C5–C6 level lends support to this explanation.

The incidence of ONL varies according to populations. In Japanese patients, the incidence of ONL ranged between 10.2% and 27.6%, whereas it is 11.3% in Koreans, 6.1% in Americans, and 4.5% in Germans [10, 11]. Kim DG et al. [12] found an incidence of 11.1% for ONL in their study where they evaluated 950 patients with cervical X-ray and cervical spine CT. Higher ONL incidence in the study by Kim DG et al. [12] compared with the present study could be due to the fact that their patient population was more homogeneous. In their study [12], the mean patient age was higher than that in present study, and they included only those patients who had cervical degenerative disease. Kim DG et al. [12] reported that the incidence of ONL was associated with other heterotopic calcifications and degenerative diseases. In Wang et al.'s study, 372 cervical spondylosis patients were evaluated with cervical X-ray and cervical spine CT, and the incidence of ONL reported to be as high as 49.7% [10]. Similar to the study by Kim DG et al. [12], Wang et al. [10] reported that ONL is more common in patients with cervical spondylosis and that the incidence increases

Age (year)	ONL-Positive n (%)	ONL-Negative n (%)	Total n (%)
<40	4 (1.90%)	206 (98.09%)	210 (100%)
40–49	5 (6.09%)	77 (93.90%)	82 (100%)
50–59	5 (8.47%)	54 (91.52%)	59 (100%)
60–69	12 (19.04%)	51 (80.95%)	63 (100%)
>69	18 (26.86%)	49 (73.13%)	67 (100%)

ONL: ossification of the nuchal ligament

with age. Scapinelli [9] reported the incidence of ONL as 6.57% in 760 radiographically studied patients. The use of radiography alone in Scapinelli's study may have resulted in missing millimetric ONLs, and the incidence could be lower due to the inclusion of a heterogeneous patient population in the study [9]. In our study, the incidence of ONL was found to be 9.1%, which is close to the lower frequency levels indicated in the literature. Relatively lower ONL incidence in the present study could be attributed to the fact that our population included relatively younger patients with different etiologies, mainly trauma.

The onset of ONL seems to start in the 3rd decade of life and peaks in the 6th [2, 3]. Scapinelli [9] did not find ONL in the cervical CT of patients in the young patient group consisting of 65 patients, and the youngest patient with ONL was 27 years old. The youngest patient with ONL in the present study, on the other hand, was 23 years old. In the studies by Kim KW et al. [13] and Wang et al. [10], ONL was most frequently detected in the age range of 50–59 years. In the present study, however, ONL was most frequently found in patients aged  $\geq 70$  years. Similar to other studies in the literature, ONL incidence in patients increased with age in the present study, and there was a significant relationship between ONL and age ( $p < 0.001$ ).

In terms of sex, ONL is reported to be more common in men. Because men tend to be more physically active than women, it is suggested that chronic overload of the cervical spine with age and cervical motion may promote ONL [9, 13]. Wang et al. [10], Kim KW et al. [13], Kim DG et al. [12], and Scapinelli [9] reported 4.0, 3.7, 3.3, and 3.2 times higher ONL incidence in men, respectively. Similar to these studies, ONL incidence in the present study was three times higher in men.

The major limitation of the present study was a relatively smaller patient population.

In conclusion, more than one sesamoid bone of different sizes can be observed in different levels of NL on CT.

**Ethics Committee Approval:** Ethics committee approval was received for this study from the ethics committee of Gaziosmanpaşa University (Number: 17-KAEK-132).

**Informed Consent:** Informed consent is not necessary due to the retrospective nature of this study.

**Peer-review:** Externally peer-reviewed.

**Author Contributions:** Concept - E.G., M.B.; Design - E.G., M.B.; Supervision - E.G.; Resource - E.G., M.B.; Materials - E.G., M.B.; Data Collection and/or Processing - E.G., M.B.; Analysis and /or Interpretation - E.G.;

Literature Search - E.G.; Writing - E.G.; Critical Reviews - E.G.

**Conflict of Interest:** No conflict of interest was declared by the authors.

**Financial Disclosure:** The authors declared that this study has received no financial support.

## References

- Kadri PA, Al-Mefty O. Anatomy of the nuchal ligament and its surgical applications. *Neurosurgery* 2007; 61: 301-4. [\[CrossRef\]](#)
- Terzi R, Özer T. Two cases with sesamoid of Nuchal ligament. *Turk J Osteoporos* 2015; 21: 167-8. [\[CrossRef\]](#)
- Paraskevas GK, Raikos A, Martoglou S, Ioannidis O. Sesamoid ossicles within the nuchal ligament: a report of two cases and review of the literature. *J Radiol Case Rep* 2011; 5: 22-9. [\[CrossRef\]](#)
- Tsai YL, Weng MC, Chen TW, Hsieh YL, Chen CH, Huang MH. Correlation between the ossification of nuchal ligament and clinical cervical disorders. *Kaohsiung J Med Sci* 2012; 28: 538-44. [\[CrossRef\]](#)
- Thomson JE. Myositis ossificans (circumscripta) in the ligamentum nuchae. *Ann Surg* 1934; 100: 279-83. [\[CrossRef\]](#)
- Posthuma de Boer J, van Wulfften Palthe AF, Stadhouder A, Bloemers FW. The Clay Shoveler's Fracture: A Case Report and Review of the Literature. *J Emerg Med* 2016; 51: 292-7. [\[CrossRef\]](#)
- Mellado JM, Larrosa R, Martín J, Yanguas N, Solanas S, Cozcolluela MR. MDCT of variations and anomalies of the neural arch and its processes: part I—pedicles, pars interarticularis, laminae, and spinous process. *AJR Am J Roentgenol* 2011; 197: W114-21. [\[CrossRef\]](#)
- Laskin WB, Fetsch JF, Miettinen M. Nuchal fibrocartilaginous pseudotumor: a clinicopathologic study of five cases and review of the literature. *Mod Pathol* 1999; 12: 663-8.
- Scapinelli R. Sesamoid bones in the ligamentum nuchae of man. *J Anat* 1963; 97: 417-22.
- Wang H, Zou F, Jiang J, Lu F, Chen W, Ma X, Xia X, Wang L. Analysis of radiography findings of ossification of nuchal ligament of cervical spine in patients with cervical spondylosis. *Spine (Phila Pa 1976)* 2014; 39: E7-E11. [\[CrossRef\]](#)
- Izawa K. Comparative roentgenographical study on the incidence of ossification of other degenerative changes of the cervical spine. Among Japanese, Koreans, Americans and Germans. *Nihon Seikeigeka Gakkai Zasshi* 1980; 54: 461-74.
- Kim DG, Oh YM, Eun JP. The Clinical Significance of Ossification of Ligamentum Nuchae in Simple Lateral Radiograph: A Correlation with Cervical Ossification of Posterior Longitudinal Ligament. *J Korean Neurosurg Soc* 2015; 58: 442-7. [\[CrossRef\]](#)
- Kim KW, Oh YM, Eun JP. Increased Prevalence of Ossification of Posterior Longitudinal Ligament and Increased Bone Mineral Density in Patients with Ossification of Nuchal Ligament. *Korean J Spine* 2016; 13: 139-43. [\[CrossRef\]](#)