

A Rare Cause and Complication of Acute Gastric Dilatation: Superior Mesenteric Artery Syndrome and Perforation

Mustafa Kemal Demir¹ , Tarik Cevher²



Cite this article as: Demir MK, Cevher T. A Rare Cause and Complication of Acute Gastric Dilatation: Superior Mesenteric Artery Syndrome and Perforation. Eurasian J Med 2017; 50: 60-1.

ORCID ID of the author:
M.K.D. 0000-0002-7023-6153.

¹Department of Radiology, Bahçeşehir University School of Medicine, Göztepe Medical Park Hospital, İstanbul, Turkey

²Department of General Surgery, Göztepe Medical Park Hospital, İstanbul, Turkey

Received: May 9, 2016
Accepted: July 13, 2016

Correspondence to: Mustafa Kemal Demir

E-mail: demir.m.k@gmail.com

DOI 10.5152/eurasianjmed.2017.17130

©Copyright 2018 by the Atatürk University School of Medicine - Available online at www.eurasianjmed.com

A 57-year-old male patient with an unremarkable medical history presented to the emergency department with a 3-day history of abdominal pain, nausea, and vomiting. On performing a physical examination, his abdomen was distended and tender to palpation. Intravenous contrast-enhanced abdominal computed tomography (CT) demonstrated acute gastric and duodenal dilatation (Figure 1a). There was narrowing of the third part of the duodenum between the abdominal aorta and the superior mesenteric artery, suggesting a diagnosis of superior mesenteric artery syndrome (Figure 1b, arrow). There was a wall defect at the posterior surface of the gastric fundus caused by acute gastric dilatation (Figures 1c and 1d, arrows), with free gas and fluid adjacent to the site of gastric perforation (Figures 1c and 1d, stars). During surgery, necrosis and a perforation were observed at the gastric fundus (Figure 1e, arrowhead). Primary suturing with an omental patch was done to close the perforation site. Duodenal decompression was performed for drainage. The patient's postoperative recovery was uneventful.

Acute gastric dilatation leading to necrosis and perforation of the stomach is very rare and may occur as a result of eating disorders, trauma resuscitation, volvulus of hiatal hernias, medications, electrolyte abnormalities, psychogenic polyphagia, and other conditions. Superior mesenteric artery syndrome is an uncommon cause of this potentially fatal disorder. Imaging is an indispensable tool in making a diagnosis. A massively dilated stomach is easily seen on performing erect plain abdominal radiography or a CT examination. A CT examination is a more accurate imaging method for identifying the causes and complications of acute gastric dilation (1, 2).

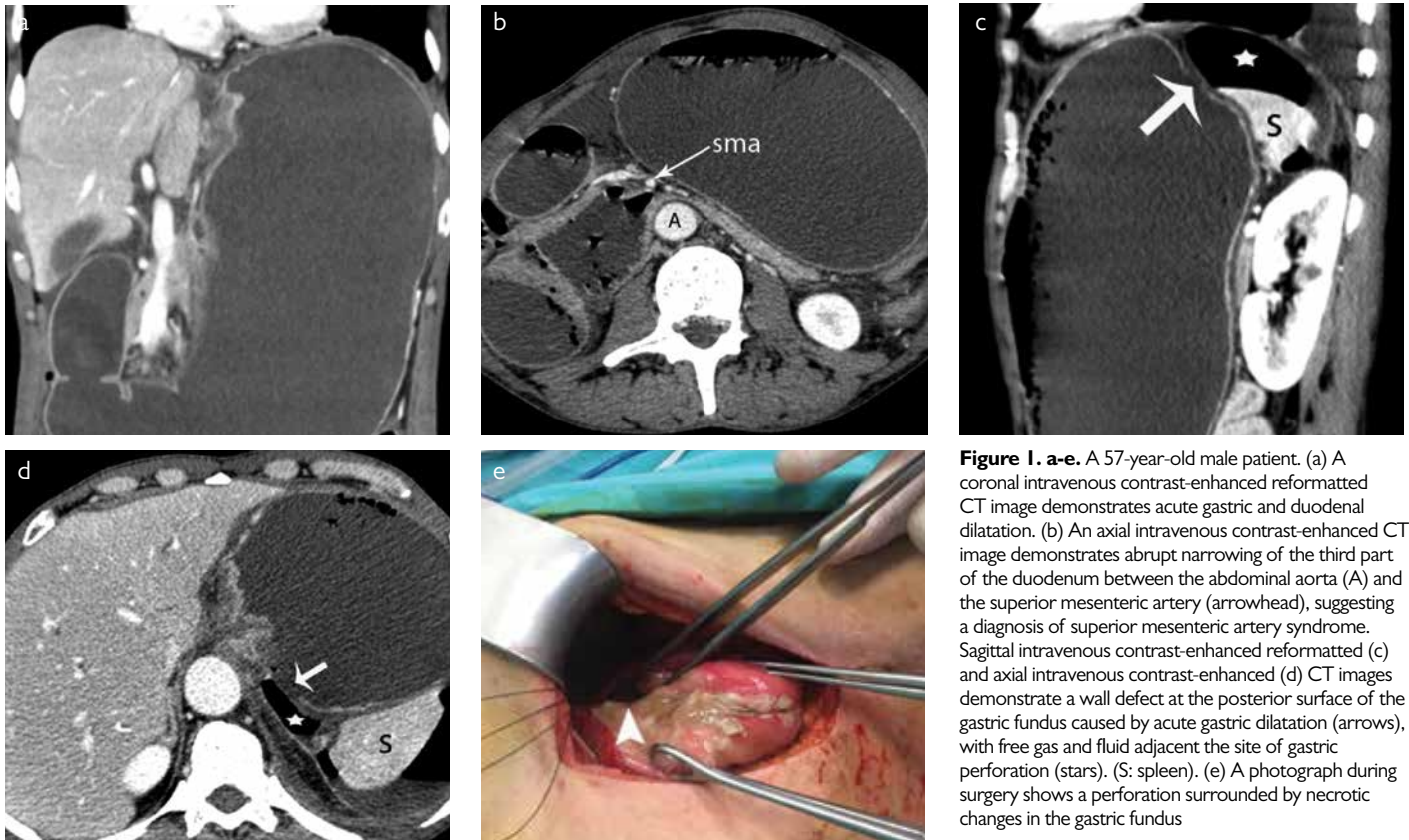


Figure 1. a-e. A 57-year-old male patient. (a) A coronal intravenous contrast-enhanced reformatted CT image demonstrates acute gastric and duodenal dilatation. (b) An axial intravenous contrast-enhanced CT image demonstrates abrupt narrowing of the third part of the duodenum between the abdominal aorta (A) and the superior mesenteric artery (arrowhead), suggesting a diagnosis of superior mesenteric artery syndrome. Sagittal intravenous contrast-enhanced (c) and axial intravenous contrast-enhanced (d) CT images demonstrate a wall defect at the posterior surface of the gastric fundus caused by acute gastric dilatation (arrows), with free gas and fluid adjacent the site of gastric perforation (stars). (S: spleen). (e) A photograph during surgery shows a perforation surrounded by necrotic changes in the gastric fundus

Informed Consent: Written informed consent was obtained from the patient who participated in this study.

Peer-review: Externally peer-reviewed.

Author Contributions: Concept - M.K.D.; Design - M.K.D.; Supervision - M.K.D., T.C.; Materials - M.K.D., T.C.; Data Collection and/or Processing - M.K.D., T.C.; Analysis and/or Interpretation - M.K.D.; Literature Search - M.K.D.; Writing Manuscript - M.K.D.; Critical Review - M.K.D., T.C.

Conflict of Interest: No conflict of interest was declared by the authors.

Financial Disclosure: The authors declared that this study has received no financial support.

References

1. Turan M, Sen M, Canbay E, Karadayi K, Yildiz E. Gastric necrosis and perforation caused by acute gastric dilatation: report of a case. *Surg Today* 2003; 33: 302-4. [\[CrossRef\]](#)
2. Gündeş E, Küçükkartallar T, Tekin A, Çakır M. Gastric necrosis and perforation caused by acute gastric dilatation. *Ulus Cerrahi Derg* 2013; 30: 179-81.