

Gastric Foregut Duplication Cyst as a Rare Cause of Abdominal Pain

Karın Ağrısının Nadir Bir Nedeni Olan Gastrik Foregut Duplikasyon Kisti

Sebahattin Sari¹, Kemal Kara², Samet Verim³, Nermin Karahan⁴

¹Clinic of Radiology, Isparta Military Hospital, Isparta, Turkey

²Clinic of Radiology, Beytepe Military Hospital, Ankara, Turkey

³Clinic of Radiology, Ankara Military Hospital, Ankara, Turkey

⁴Department of Pathology, Faculty of Medicine, Suleyman Demirel University, Isparta, Turkey

Abstract

Gastric foregut cyst is a rare congenital disease. In this report, a gastric foregut cyst in a 22-year-old male patient is presented. Fluid-filled gastric ultrasonography and computed tomography demonstrated a cystic, calcified lesion attached to the anterior gastric wall. The same lesion was observed using upper gastrointestinal endoscopy. An exploratory laparotomy revealed a non-communicating cyst. The cyst was excised surgically, and pathology confirmed the diagnosis.

Key Words: Computed tomography, Foregut cyst, Stomach, Ultrasonography

Özet

Gastrik foregut kisti nadir bir konjenital hastalıktır. Bu makalede, 22 yaşında erkek bir olgudaki gastrik foregut kisti sunulmaktadır. Abdominal ultrasonografi mide sıvı ile tamamen doldurulduktan sonar yapılmıştır. Ultrasonografi ve bilgisayarlı tomografi incelemelerinde anterior mide duvarına yapışık olan kalsifiye kistik lezyon tespit edilmiştir. Aynı lezyon üst gastrointestinal sistem endoskopik incelemesinde de görülmüştür. Eksploratif laparotomide non-kommunike kistik lezyon saptanmıştır. Kist cerrahi olarak eksize edilmiş ve tanı patolojik olarak doğrulanmıştır.

Anhtar Kelimeler: Bilgisayarlı tomografi, Foregut kisti, Mide, Ultrasonografi

Introduction

A wide spectrum of anomalies affects the upper gastrointestinal tract, including the esophagus, stomach, and duodenum. Gastrointestinal (GI) foregut cysts are rare. As a general definition, a gastrointestinal foregut duplication cyst is a spherical hollow structure with a smooth muscle coat that is lined by a mucous membrane and attached to any part of the gastrointestinal tract [1]. Foregut cysts may or may not communicate with the GI tract and are typically diagnosed at a young age; in adults, non-specific symptoms delay diagnosis, which is typically confirmed during surgical exploration [2].

Patient evaluation can require multiple imaging modalities, including ultrasonography, computed tomography, gastrointestinal barium studies and endoscopy. Radiological examinations, including ultrasonography and computed tomography, are often diagnostic and specific and typically provide important diagnostic information.

In this report, a case of a gastric foregut duplication cyst presenting with atypical abdominal pain is presented.

Case Report

A 22-year-old male patient was admitted to our hospital complaining of upper abdominal pain. The patient's medical history and physical examination were non-specific. The diagnostic workup included abdominal ultrasonography, which demonstrated a circumscribed cystic lesion with a partially calcified wall measuring 2x2x3 cm attached to the anterior wall of the lesser curvature (Figure 1). Fluid-filled gastric ultrasonography clearly demonstrated a lesion that was also observed using computed tomography in anatomic detail (Figure 2). Moreover, upper GI endoscopy showed a spherical mass that extended into the lumen without any mucosal abnormalities (Figure 3). Surgical intervention was performed and revealed a cystic lesion attached to the lesser curvature. The post-operative course was uneventful, and the patient has since been asymptomatic. A pathological examination demonstrated that the cyst consisted of a smooth muscular wall that was lined by a ciliated columnar epithelium and contained clear gelatinous fluid (Figure 4).

Received: July 05, 2012 / **Accepted:** September 13, 2012

Correspondence to: Kemal Kara, Clinic of Radiology, Beytepe Military Hospital, Ankara, Turkey

Phone: +90 549 549 12 34 Fax: +90 312 278 52 54 e-mail: drkemalkara@yahoo.com

doi:10.5152/eajm.2012.43

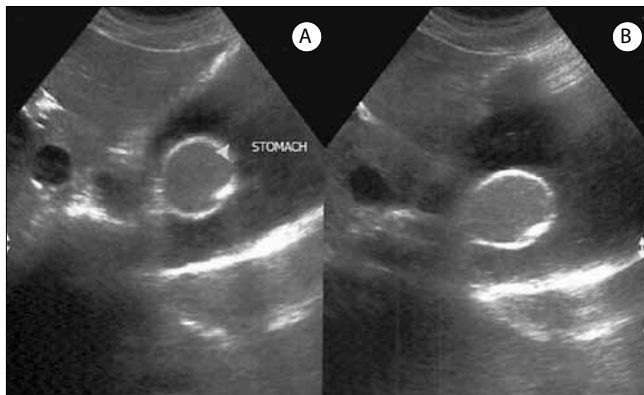


Figure 1. Ultrasonographic images showing a circumscribed cystic lesion (arrowhead) with a partially calcified wall attached to the anterior wall of the lesser curvature.

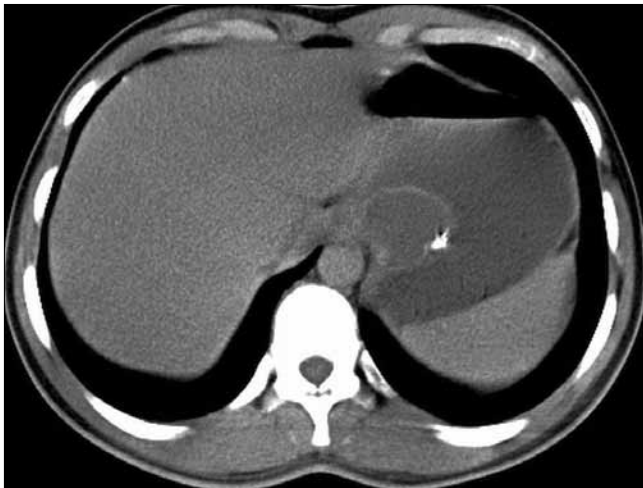


Figure 2. An axial CT image showing a cystic mass with a partially calcified wall attached to the posteromedial portion of the stomach.

Discussion

Duplications of the stomach account for approximately 7% of gastrointestinal duplications, and they occur twice as frequently in females as in males [3, 4]. Most are non-communicating, single and located on the greater curvature. Wiczorek et al. [5] reported that gastric duplications could be tubular or cystic. Wendel [6] published the first case report of a gastric duplication in 1911, and approximately 150 cases have been reported to date.

However, due to their non-specific clinical findings, diagnosis may be difficult. A wide range of symptoms and signs have been reported, and patients vary from being asymptomatic to having non-disease-specific presentations, e.g., vague abdominal complaints, nausea, vomiting, epigastric fullness, weight loss, and anemia [7]. In our case, the male patient presented with only abdominal pain.

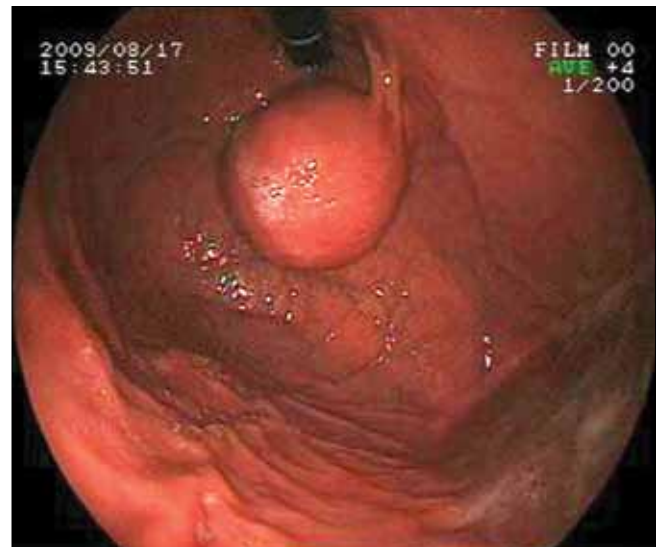


Figure 3. An endoscopic image showing a spherical mass protruding into the lumen without any mucosal abnormalities.

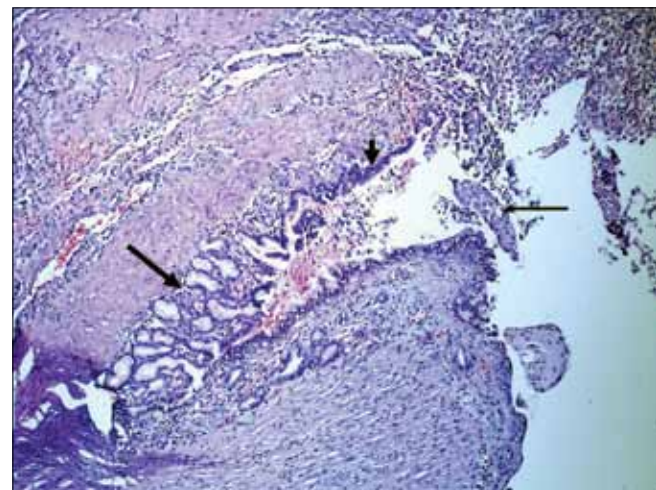


Figure 4. A microscopic view of the pathologic specimen (HE4X). Long thick arrow: gastric mucosa; short arrow: ciliated columnar epithelium of cyst surface; long thin arrow: stratified squamous epithelium.

Foregut duplication cysts of the stomach are typically diagnosed incidentally. The diagnostic workup primarily includes abdominal ultrasonography and computed tomography as well as endoscopic ultrasonography and magnetic resonance imaging [8]. In our case, abdominal ultrasonography performed on a fluid-filled stomach provided important diagnostic information that was not provided by computed tomography and gastric endoscopy. Fluid-filled gastric ultrasonography played a crucial role in detecting the gastric wall mass.

Due to malignant transformation and a previous report of gastric cancer arising in duplications of the stomach, surgical

excision is considered to be the best treatment [9]. Complete resection of the cyst is the ideal technique for treatment [10].

In conclusion, foregut duplication cysts of the stomach are rare but should be considered in the differential diagnoses of patients with vague upper abdominal pain. In addition, a fluid-filled gastric ultrasonographic examination should be performed in patients presenting atypical upper abdominal pain.

Conflict of interest statement: The authors declare that they have no conflict of interest to the publication of this article.

References

1. Glaser C, Kuzinkovas V, Maurer C, Glattli A, Mouton WG, Baer HU. A large duplication cyst of the stomach in an adult presenting as pancreatic pseudocyst. *Dig Surg* 1998; 15: 703-6.
2. Perek A, Perek S, Kapan M, Goksoy E. Gastric duplication cyst. *Dig Surg* 2000; 17: 634-6. [\[CrossRef\]](#)
3. Pruksapong C, Donovan RJ, Pinit A, Heldrich FJ. Gastric duplication. *J Pediatr Surg* 1979; 14: 83-5. [\[CrossRef\]](#)
4. Chawla A, Gadaleta D, Kenigsberg K, Kahn E, Markowitz J. Erosion through the posterior gastric wall by a pancreatic pseudocyst secondary to gastric duplication. *J Pediatr Gastroenterol Nutr* 1991; 13: 115-8. [\[CrossRef\]](#)
5. Wieczorek RL, Seidman I, Ranson JH, Ruoff M. Congenital duplication of the stomach: case report and review of the English literature. *Am J Gastroenterol* 1984; 79: 597-602.
6. Wendel W. Beschreibung eines operativ entfernten congenitalen Nebenmagens. *Arch Klin Chir* 1911; 96: 895-8.
7. Stephen TC, Bendon RW, Nagaraj HS, Sachdeva R. Antral duplication cyst: a cause of hypergastrinemia, recurrent peptic ulceration, and hemorrhage. *J Pediatr Gastroenterol Nutr* 1998; 26: 216-8. [\[CrossRef\]](#)
8. Tanaka M, Akahoshi K, Chijiwa Y, Sasaki I, Nawata H. Diagnostic value of endoscopic ultrasonography in an unusual case of gastric cyst. *Am J Gastroenterol* 1995; 90: 662-6.
9. Kuraoka K, Nakayama H, Kagawa T, Ichikawa T, Yasui W. Adenocarcinoma arising from a gastric duplication cyst with invasion to the stomach: a case report with literature review. *J Clin Pathol* 2004; 57: 428-31. [\[CrossRef\]](#)
10. Holcomb GW 3rd, Gheissari A, O'Neill JA Jr, Shorter NA, Bishop HC. Surgical management of alimentary tract duplications. *Ann Surg* 1989; 209: 167-74. [\[CrossRef\]](#)